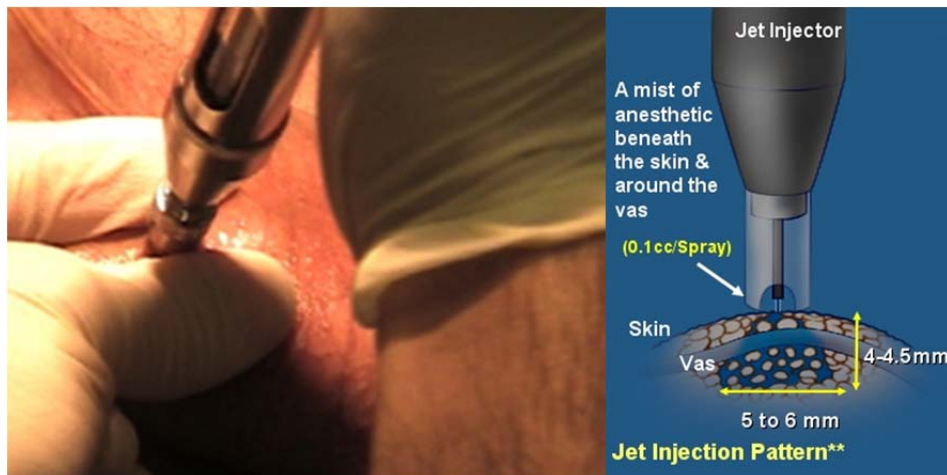


No-Needle Anaesthesia for No-Scalpel Vasectomy: *An Instructive Guide for Surgeons*

Ronald S. Weiss, M.D.

Philip S. Li, M.D.



Copyright © 2011

The Weiss Clinic, Ottawa, Canada

About the Authors

Dr. Ronald S. Weiss



Dr. Weiss is Assistant Professor of Medicine in the Department of Family Medicine, University of Ottawa School of Medicine, President of No-Scalpel Vasectomy Inc., and President of The Weiss Clinic. Family Physician, teacher and leader in the field of male surgical contraception and erectile dysfunction in Canada, he introduced No-Scalpel Vasectomy to Canadian physicians in 1992 and trained most of those practicing the technique today. He developed and refined a method of no-needle jet anaesthesia for no-scalpel vasectomy and has completed over 16,000 no-scalpel vasectomies since 1992. Dr. Weiss has served as an advisor to the W.H.O. in the investigation of newer methods of male surgical sterilization including RISUG in India. He has lectured widely on no-scalpel vasectomy, erectile dysfunction, cyano-acrylate use, critical appraisal and jet injection anaesthesia. He is past president of the medical staff for the largest long-term care institution in Canada. Dr. Weiss has developed a hands-free local anaesthetic bottle support and has contributed to the development of cautery devices, both AC & DC, and a 2-octyl cyanoacrylate glue. He has been interviewed and quoted in national and international media on a variety of subjects related to his work. A member of the Canadian Male Sexual Health Council, Dr. Weiss has contributed to the major educational initiatives on male health and erectile dysfunction in Canada.

Dr. Philip S. Li



Dr. Philip S. Li is an Associate Research Professor of Urology and Reproductive Medicine; and Director of Microsurgical Research and Training Program at the Center for Male Reproductive Medicine and Microsurgery, Cornell Institute for Reproductive Medicine, and Department of Urology, at Weill Cornell Medical College of Cornell University. Dr. Li is an internationally recognized expert in the no-scalpel vasectomy (NSV) and a leading researcher in microsurgery and male reproductive physiology. Dr. Li was one of the key figures in developing the AVSC International surgical manual and protocol for NSV techniques, which has become a standard technique for vasectomy in the U.S. He has personally trained several hundred urologists, surgeons and family practitioners to perform NSV worldwide. He has authored or co-authored over 86 papers in peer-reviewed journals, books, and book chapters on topics related to male reproductive medicine and microsurgery. He has presented over 80 abstracts on topics of male infertility and microsurgical techniques at national and international medical conferences. Dr. Li has pioneered several microsurgical techniques for male infertility treatment and performed numerous research projects under the guidance of Dr. Marc Goldstein and Dr. Peter Schlegel. He established the Cornell Brady Urology Studio and has directed and produced over 42 medical videos and DVDs for male infertility and urological microsurgical techniques and treatment over the past ten years. Many of these multimedia tapes and DVDs were awarded The Best Urology Video Prize at the American Society for Reproductive Medicine (ASRM, 1998, 2006). He received The First Prize (2002 and 2003), 2nd prize (2010) and 3rd Prize video (2009) at the American Urologic Association (AUA) national meeting. He also received the first prize video at the annual meeting of the Society of Laparoendoscopic Surgeons (SLS) in 2007. In addition, Dr. Li has been actively involved in nearly all new development and refinement of microsurgical techniques currently used at Weill Cornell Medical College/New York-Presbyterian Hospital for treating male infertility.

CAUTION!!

No-needle jet anaesthesia eliminates the risk of needle-stick injury. However, there remains the possibility of accidental self-injection.

To avoid injury to yourself and/or your patient, please:

- **Read this instruction manual thoroughly before attempting to use your jet injector**
- **Always wear finger protection**
- **Make certain that the filling chamber of your jet Injector has an adequate volume of anaesthetic solution prior to cocking the lever**
- **Always hold the injector in the vertical position (release button up, tip down) when cocking the lever**

Table of Contents

About the Authors

Dr. Ronald S. Weiss 2

Dr. Philip S. Li 2

Caution 3

No-Needle Anaesthesia for No-Scalpel Vasectomy 5

Introduction 5

Method 6

Notes and Tips 5

Troubleshooting 9

Pictorial Atlas for No-Needle Anaesthesia 11

References 15

(No part of this book may be reproduced in any form by any electronic or mechanic means (including photocopying, recording, or information storage and retrieval) without permission in writing from the publisher.)

No-Needle Anaesthesia for No-Scalpel Vasectomy

Introduction

There's something remarkable about being able to provide profound local anaesthesia without resorting to the use of a needle. We have become so accustomed to believing that this is the only "real" method to deliver anaesthesia, which it is nothing short of extraordinary to witness otherwise. When originally developed by Dr. Robert Hingson (Figure 1) as the "hypospray", straight out of Star Trek, it seemed a futuristic improbability...like a better mouse trap. But a better mouse trap it appears to be, capable of delivering a profound numbing, with a fraction of the volume of anaesthetic solution and in a fraction of the time compared to needle delivery. Best of all, men who fear



the needle are reassured and perhaps more likely to consider vasectomy as an option for permanent birth control once their families are complete.

Vasectomy is a safe and effective method of permanent male contraception. In the United States, it is employed by nearly 7% of all married couples and performed on approximately one-half million men per year, more than any other urological surgical procedure.

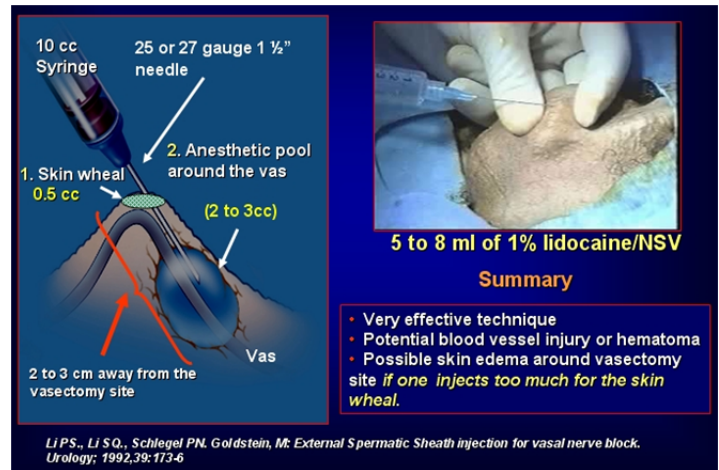
Historically, some men have shied away from vasectomy because they fear the pain and possible complications. In clinical practice, however, one of the commonest voiced concerns is that of 'the needle' for injection of local anaesthetic into and through the scrotal skin. Efforts to

Vasectomy: USA and Canada

- A safe, simple and effective surgical approach
- Over 7% of all married couples
- Approximately 500,000 to 800,000 vasectomies per year
- Number **one** urological procedure

enhance the popularity of vasectomy have led the Chinese to develop refined methods of no-scalpel vasectomy that minimize trauma, pain and

complications^{1, 2, 3, 4, 5}. The introduction of 'no-scalpel' vasectomy has successfully allayed many men's fears with regard to the scalpel. The success of the Chinese in attaining these goals is evidenced by a complete reversal of the ratio of male to female sterilizations (now 3:1, respectively) in favor of vasectomy in the Sichuan province of China⁶.

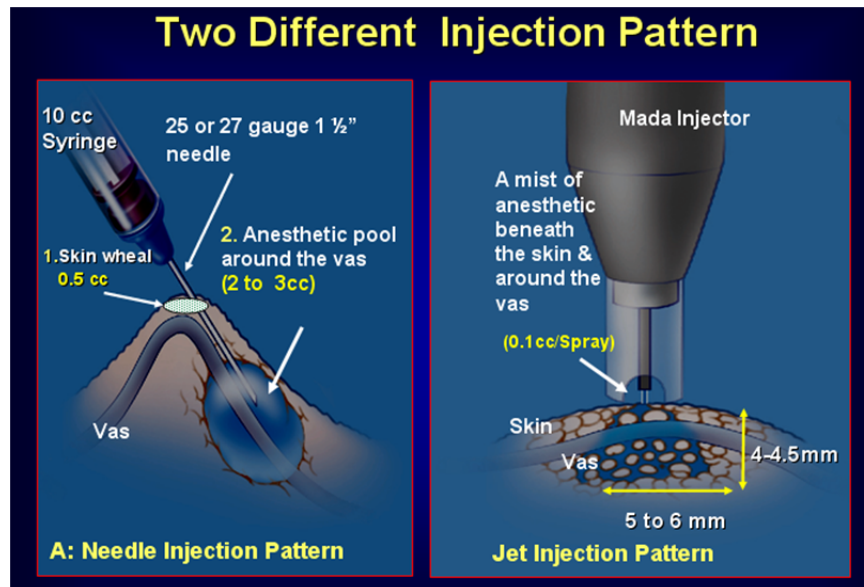


The option of receiving local anaesthesia without a needle is a particularly welcome one for many men, which may have some significant advantages for the popularity of vasectomy. Conventional vasal block needle anaesthesia in no-scalpel vasectomy involves the use of a 25 or 27 gauge 1 1/2" needle used to raise a wheal at the median raphe at the junction of the upper 1/3 and lower 2/3rds of the scrotum; it is then advanced its full length toward the external inguinal ring on each side where further anaesthetic solution is deposited⁷.

Weiss and Li modified and refined the jet injection technique for vasectomy described in this manual, attaining a close to 100% efficacy rate with no need for supplemental anaesthetic^{8,9}. The goal of this no-needle jet anesthesia approach is to simplify the surgical technique and to reduce men's fear of vasectomy.

Method

1. General Preparation: A warm room temperature (20C° to 25C°) is set up in advance to facilitate relaxation of the scrotal skin. A thin, relaxed scrotum will assist in both the administration of anaesthesia and the performance of the no-scalpel vasectomy.



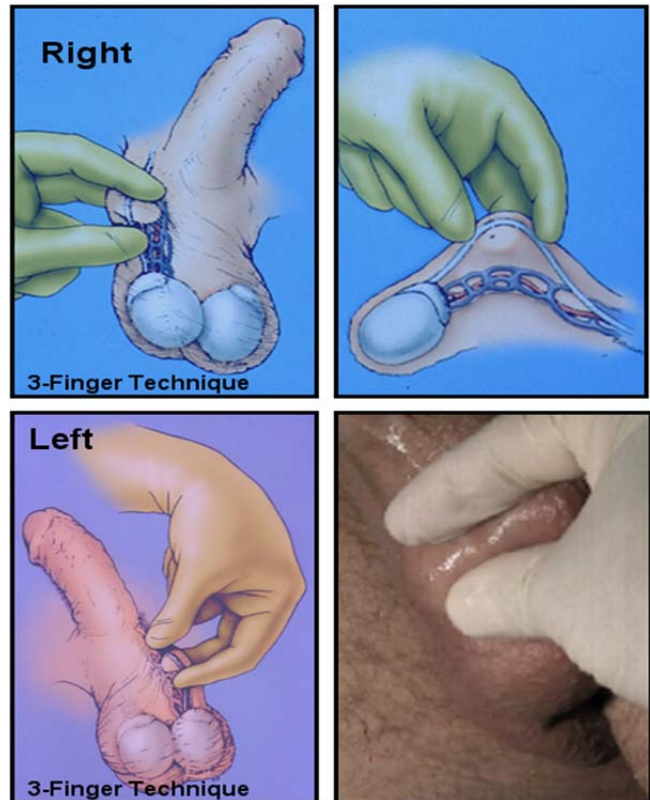

The scrotal skin is shaved, preferably in advance, and the penis is retracted by means of a

rubber band placed around the glans and secured with a clamp to the patient's shirt.

2. Jet Injector Preparation: The MadaJet® (MADA Medical Products, Carlstadt) has been widely used in the fields of dermatology, cosmetic and plastic surgery, gynecology, dentistry and podiatry^{10, 11, 12, 13, 14}.

The Mada injector and its components are fully auto-clavable for the purpose of sterilization. So, following sterilization, using sterile technique, a drop of lidocaine solution is placed over the seal on the injector head to promote a good seal with the filling chamber and the filling chamber is filled with approximately 4 cc of anaesthetic solution, 2% lidocaine without epinephrine. The jet injector assembly is then attached to the filling chamber. The main injector assembly is pumped back and forth, then fired several times in order to "prime" the mechanism and to clear any potential debris or contaminants from the tip prior to first use after filling. When filled to capacity, the injector should have sufficient solution for about four cases using the technique described. A grooved spacer/sheath, specially designed to accommodate the diameter of the vas, is fixed over the tip of the injector.

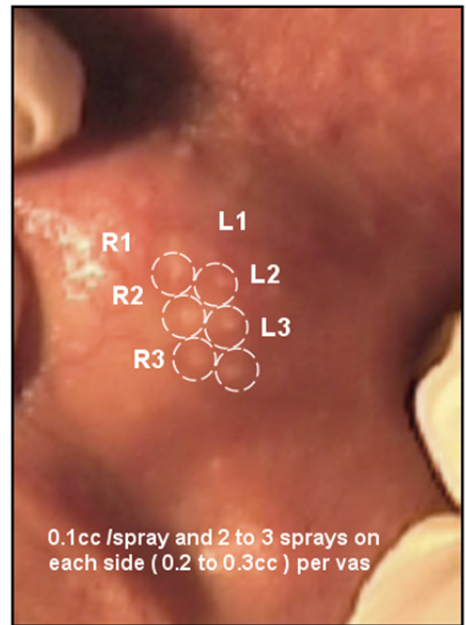
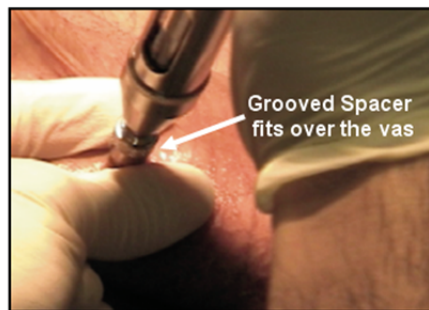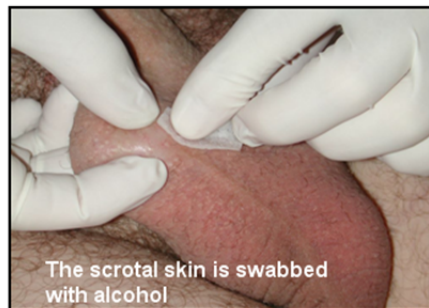3. Surgical Preparation: To ensure the jet injector functions well, the pre-loaded injector is fired once immediately before each case.



With the surgeon standing on the patient's right side, using standard no-scalpel vasectomy 3-finger technique (and using the protective finger cot), the vas is firmly trapped between the middle finger, the index finger and thumb of the left hand thus fixing the right vas and separating it from the spermatic cord vessels and manipulating it to a superficial position under the scrotal skin at the median raphe.

After the scrotal skin is swabbed with alcohol, the spacer-covered tip of the injector is placed with groove fitting over the vas, firmly but gently, just to the left lateral aspect of the median raphe at the junction of the upper 1/3rd and lower 2/3rds of the scrotum.

Accurate placement may be confirmed with a slight lateral movement of the tip against the vas...the back and forth movement should move the vas as well and be perceived by the grasping fingers. Three injections are administered sequentially, proceeding from proximal to distal, 4-5mm apart along the left lateral aspect of the median raphe.



The left vas deferens is grasped in a similar fashion with 3 sequential injections, proceeding from proximal to distal, 4-5mm apart now along the right lateral aspect of the median raphe at the junction of the upper 1/3 and lower 2/3rds of the scrotum and adjacent to the previous 3 injections conventional vasal block with needle injection for no-scalpel vasectomy, there is no skin wheal or local edema to pinch following the administration of the anaesthetic. Moreover, jet injection results in a completely different dispersal pattern. The lidocaine solution is forced through a tiny opening under high pressure. What exits is a very fine stream which acts as a virtual needle and passes through the skin without difficulty.

The difference between this and a steel needle delivery system is that the jet stream expands in a cone-shaped distribution as it passes through the skin and subcutaneous tissue down to a

depth of penetration of up to 6mm, perfusing all the tissues in its path. The sensation is often described as not unlike a small rubber band against the skin. More importantly, the anaesthetic effect takes just seconds and is more profound than that achieved with conventional needle delivery. The injection sites are identified by pin-point areas of slight blanching. The jet injector is fired after patient anaesthesia and must be disinfected appropriately (e.g. with soaking in Madacide-FD® solution) prior to next use. The spacer/sheath is changed between patients and may be sterilized for repeated use.

The injections are placed such that the right vas is brought up and injected just under the left lateral aspect of the median raphe and the left vas is brought up and injected just under the right lateral aspect of the median raphe. This achieves two results. Firstly, the surface anaesthesia may be described as a series of intersecting circles at each of the injection points. The four to six intersecting circles provide sufficient surface anaesthesia for performing the initial skin puncture and spreading in no-scalpel vasectomy technique. Secondly, there will be sufficient anaesthesia of the scrotal septum by this 'cross' anaesthesia further reducing the risk of intra-operative discomfort.

After the completion of "jet" injection anaesthesia, the patient may be sterile prepped and draped and proceed to vasectomy without further delay.

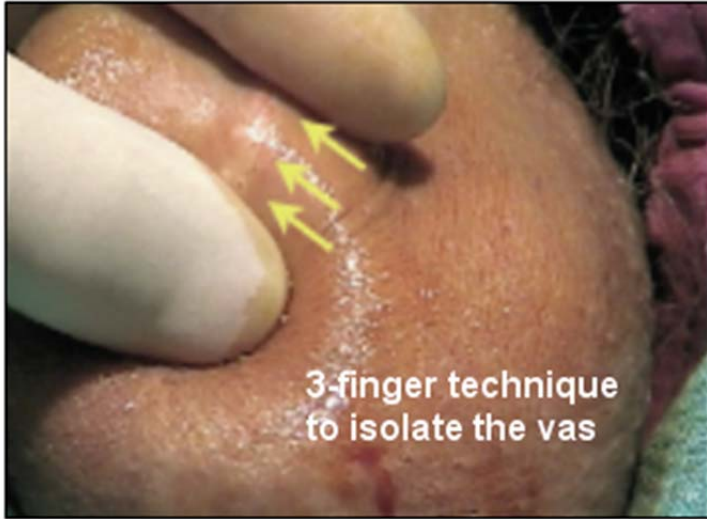

Notes and Tips

The no-needle anaesthesia technique comprises a series of precise maneuvers executed in a specific sequence, not unlike no-scalpel vasectomy. With attention and adherence to detail, the practitioner should achieve adequate proficiency upon completion of about 10 cases. The author cautions the user to observe these steps as described in order to achieve the desired result of a painless vasectomy with minimal risk to surgeon or patient. The major advantages of this jet injection technique are:

1. Anaesthesia with 1/10th the volume of lidocaine normally required when using a needle.

2. Rapid onset (seconds vs. minutes with a needle).
3. Profound anaesthetic effect resulting in a virtually painless vasectomy.
4. Elimination of the needle with subsequent reduction of men's fear of vasectomy.



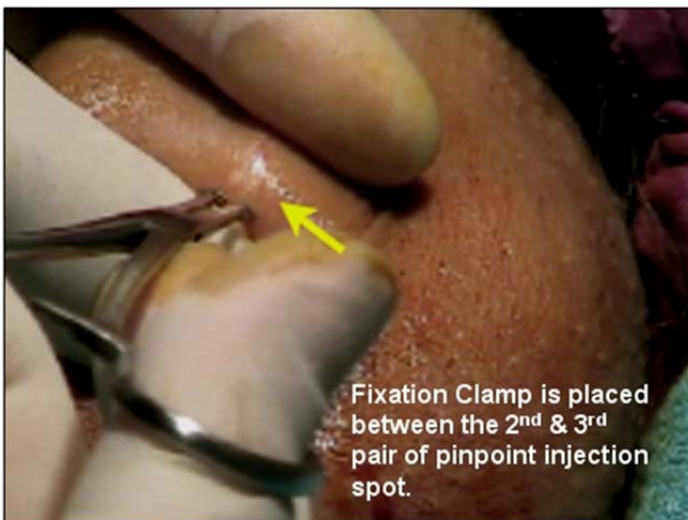
The injection itself leaves a pinpoint mark at the entry site that is easily recognizable in most men. This is less obvious in men of color and the surgeon may choose to mark the scrotum with a marking pen in these cases in order not to lose the area of anaesthetic application.

Another means of “finding the spot” to apply the ring clamp following anaesthesia, is to squeeze gently in the likely area, expressing

a small drop of blood from the entry points and thus revealing them. There are cases where the median raphe is not pigmented or easily identified once the surgeon has applied the 3-finger technique. In these cases it is appropriate to simply “guesstimate” the desired area of application of anaesthesia.

It is highly recommended that 3-finger technique be respected. By doing so, the surgeon displaces the vas away from other scrotal structures. The variable vessel that travels with the

vas is also thus protected beneath the crest of the loop of vas as it is tented up. Furthermore, the force of the jet stream can cause the vas to roll to one side or another. The combination of 3-finger technique and the use of a specially designed grooved spacer will reduce the possibility of rolling. This is significant in that rolling of the vas may increase the risk of chord hematoma (because the vas is not absorbing the *impact*



of the stream) and reduce anaesthetic efficacy (because the vas is not absorbing the *bulk* of the stream). Chord hematoma may occur if the injector is fired in the same location more than once. Never fire the injector in the same exact location more than once! It is advisable to avoid superficial skin vessels where possible.

There are rare cases where jet injection anaesthesia is less effective than the use of a needle. In particular where there has been previous scrotal surgery with adhesion (e.g. previous vasectomy, vasovasostomy), the surgeon would do better to use conventional vasal block by needle. Where the scrotal skin is thickened and ruddy, often from chronic habit scratching, one may witness excessive blanching of the skin on application of the jet injector. This indicates that the lidocaine is being deposited more superficially as a function of the tissue resistance. Again, in these rare cases the operator is better off using conventional needle anaesthesia delivery. Where a testicle is located high in the scrotum and/or the vas is tight and short, it may be technically difficult to apply the jet injector, as it would be to use a needle. The surgeon must use their best judgment in these atypical cases.

The jet injectors themselves require regular cleaning, maintenance and inspection. The MadaJet® System (MADA Medical Products, Inc. Carlstadt, NJ) should be disinfected between



patients in a Madacide-FD® or other disinfectant approved by MADA (cold sterilization/disinfection times vary by solution, manufacturer's instructions should be followed). The stainless steel sheath must be sterilized between patients. The injectors and their components should be flushed with distilled or demineralized water, ultrasonic cleaned and autoclaved each day of use (the main body of the injector unit should be only partially immersed for ultrasonic cleaning so

that no liquid enters the spring chamber). Firing the injectors both before and after use helps to clear any possible debris. Over time, with use and maintenance, the head assembly will fit and function best with its original injector body. Care should be taken to maintain the same pairing of heads and bodies if the practitioner owns more than one injector.

With continued use, wear and tear will cause deterioration of the numerous rubber O-rings that

maintain seals within the unit. As a result, the unit will not function properly and the anaesthetic effect will be compromised. The manufacturer can replace the worn seals and provide other maintenance chores. Pay attention to the sound of the injector when it fires. Under normal circumstances, each shot produces a quiet “phhht” sound. With time and wear, this may turn into a louder popping sound. The onset of “popping” may signal time for maintenance. The combination of popping and reduced anaesthetic effect is a sure sign of need for servicing of the unit.

These guidelines apply to the MadaJet® straight head injector. The pressure setting may be adjusted by request. There have been suggestions over time that a “low” pressure may be “safer”. One could make the analogy with a scalpel blade. If one made a scalpel blunt, it would be “safe” but wouldn’t do the job. Most surgeons want a sharp scalpel. It is more the technique of how the scalpel is applied than its sharpness that determines efficacy and complications. Extensive study and trial involving over 6,000 patient uses over several years was used to determine the optimal setting and technique for no-needle anaesthesia for no-scalpel vasectomy. Lower pressure settings and different technique, though one might think otherwise, may lead to passage of the jet stream through the scrotum and diminished anaesthetic effect⁸.

While the jet injector eliminates needle stick injury and syringe waste management, it introduces the possibility of self-injection of the operator’s third digit through such an exit wound, though this is exceedingly rare when using the 3-finger no-scalpel vasectomy technique exactly as described. This can occur when the injector is empty or close to empty of anaesthetic solution, or with malfunction (also rare) of the unit. It must be stressed that the injector be vertical when cocked and this becomes more critical as it approaches the empty state (a full chamber can provide enough anaesthetic for 3-4 cases when used as described). However, the theoretical possibility of an exit wound still exists and the surgeon is advised to protect his or her self.



The use of a protective finger cot may provide protection. Custom molded finger cots are available for this purpose¹. Unfortunately, the use of a finger cot creates an insensate barrier to the third digit when palpating the vas deferens. The surgeon may find it takes some time to adapt. With time, however, it will become second nature.

Troubleshooting

The injector should be maintained in a vertical or near vertical position at all times. This prevents liquid from entering the upper spring chamber and ensures that anaesthetic solution enters the head assembly when the lever is cocked. If the filling chamber is nearly empty, this is particularly crucial. If insufficient solution is available, as occurs if the injector is cocked in a horizontal or empty context, the anaesthetic effect may be diminished.

If the vas is not anchored adequately with 3-finger technique, it may tend to roll. The anaesthetic solution is displaced, with less than adequate numbing as a result, and there may be increased risk of chord hematoma.

Thickened and ruddy scrotal skin, or prior scrotal surgery with resultant scar tissue, will impede the jet stream and reduce efficacy. In the former case one will often notice excessive blanching of the scrotal skin surface with each injection.

The vas can have a tendency to roll as a function of the jet stream pushing it to one side or another. Good 3-finger technique and the use of a specially grooved spacer together serve to anchor the vas making movement, or rolling, unlikely. Rolling may also result in passage of the jet stream along adjacent vessels and resultant chord hematoma.

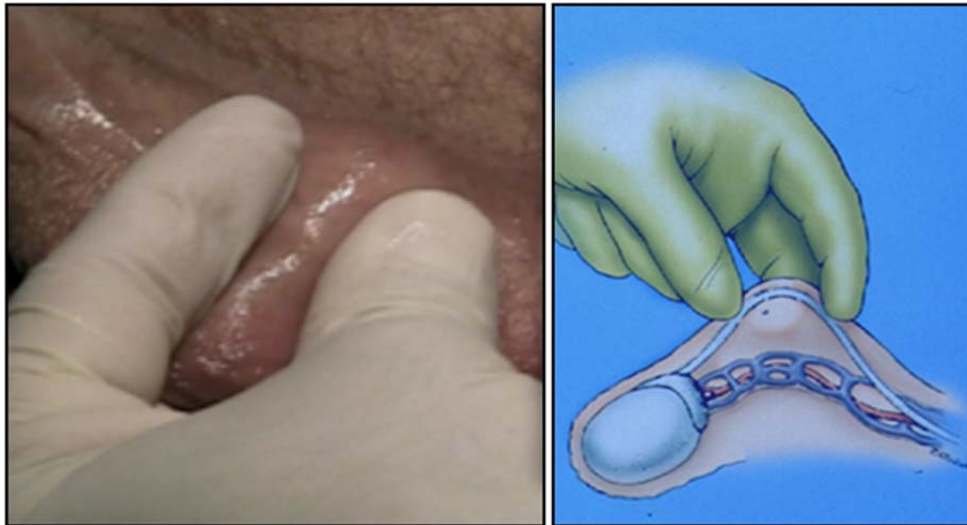
Failure to achieve adequate numbing after a series of successful cases may indicate need for servicing of equipment as a result of wear and tear on the sealing rings. The ExtendaTip® will require replacement if the stream it emits is not clean and straight replacement is indicated if the stream appears fuzzy.

The ExtendaTip® must be securely tightened on the nose assembly. The ExtendaTip® may require tightening with the supplied miniature wrench following shipment to you (as evidenced by the exit of solution from around the ExtendaTip® nut seal during firing). Service is recommended at least annually. Regular ultrasonic cleaning prolongs the life of the injector components.

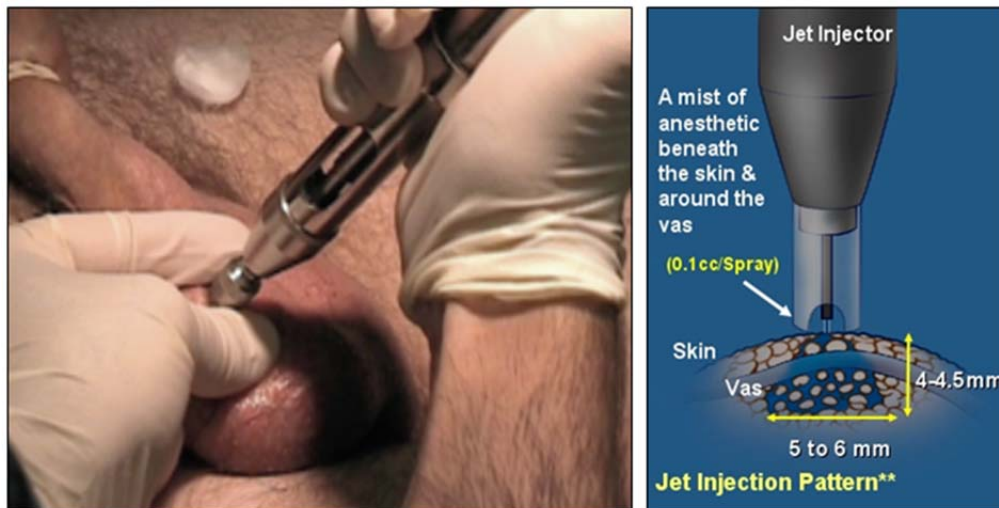


Pictorial Atlas for No-Needle Anaesthesia


1. The scrotal skin is cleansed with alcohol and the right vas deferens is isolated using standard No-Scalpel Vasectomy 3 finger technique.



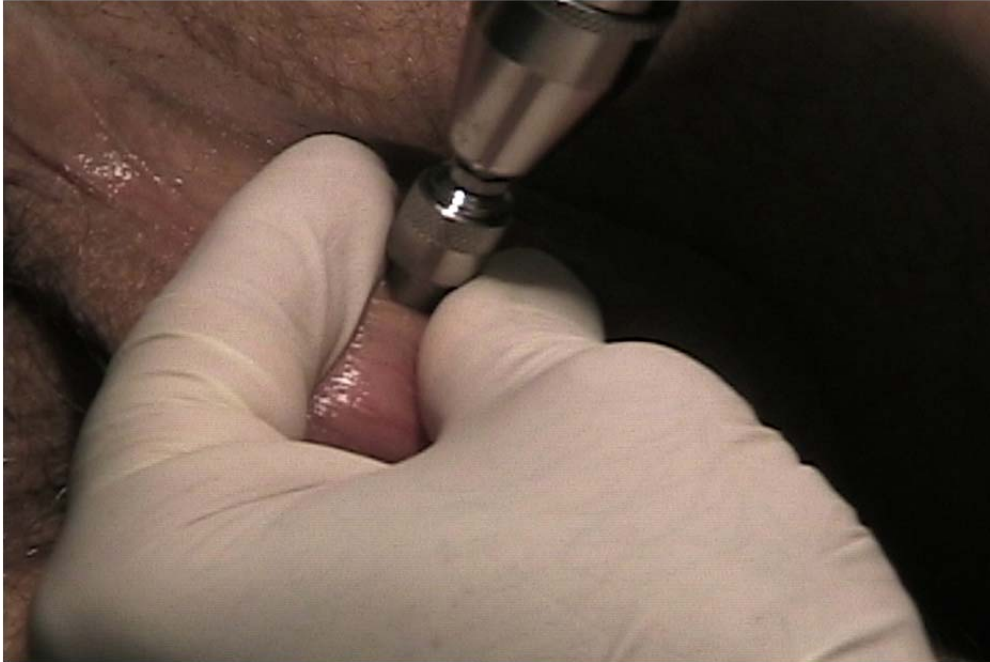2. The first injection is made over the right vas deferens at the median raphe at the junction of the upper 1/3 and lower 2/3rds of the scrotum.



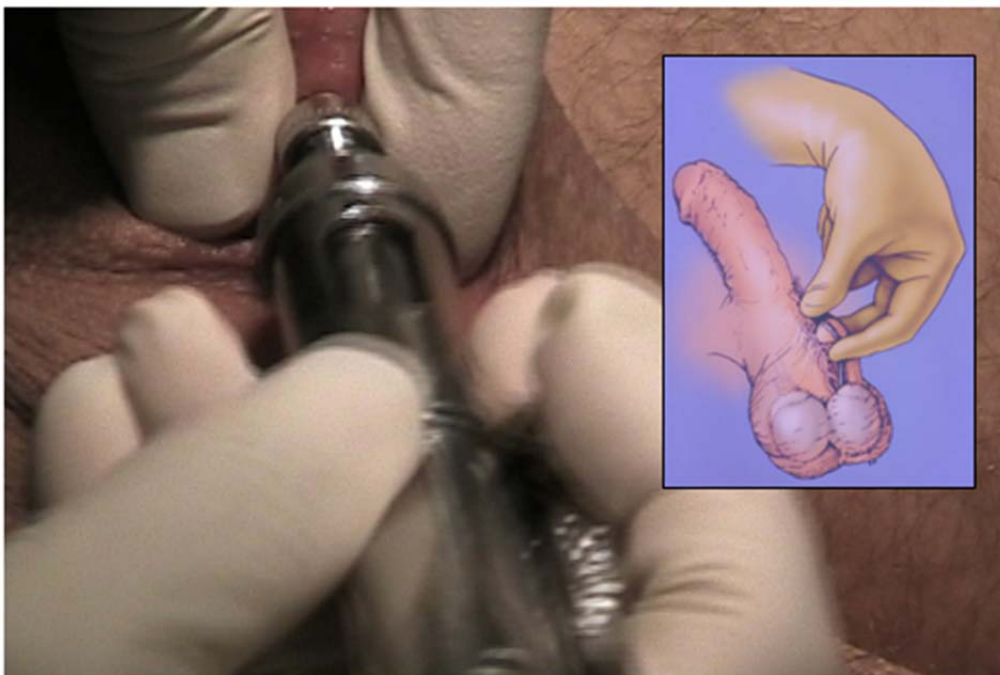
3. Without releasing the 3-finger hold, the injector lever is re-cocked against the physician's left thenar eminence.



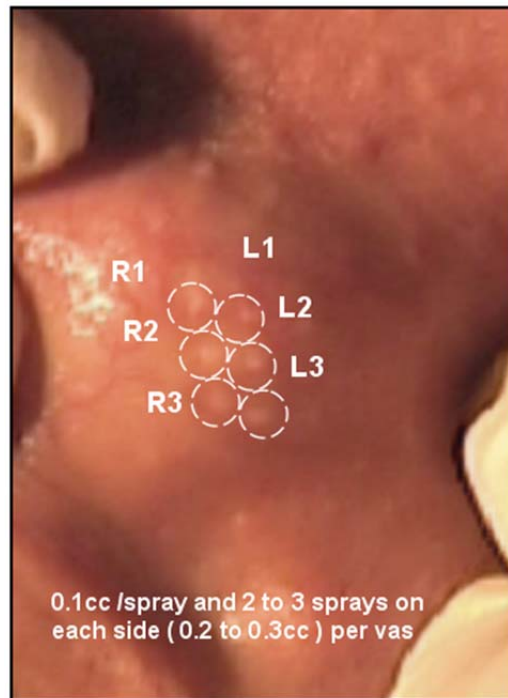
4. Two more injections are made 3-5mm apart going distally from the first injection.



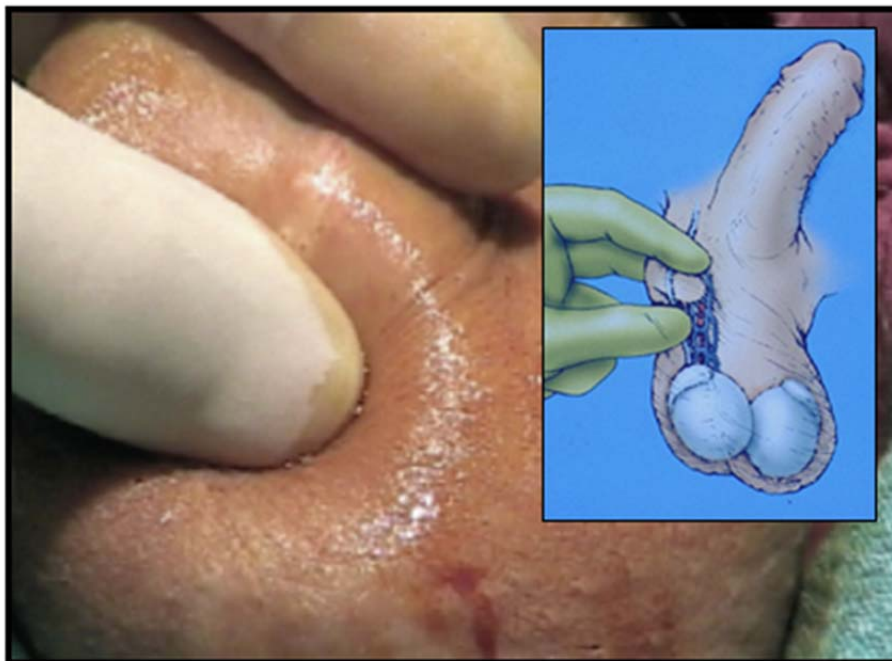
5. Similarly, the left vas deferens is grasped using 3-finger technique and the process of three injections is repeated on the left side.



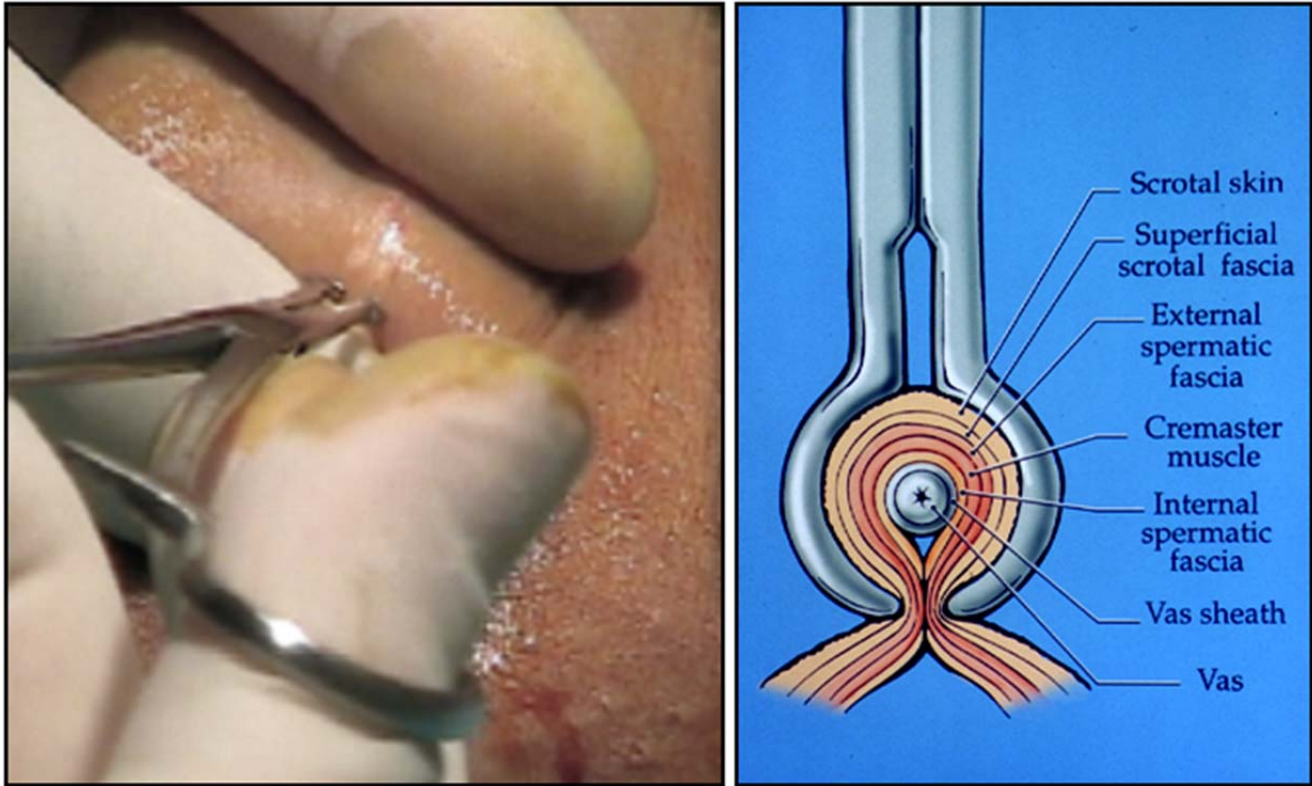
6. Each injection point is identified as a pin-point area of blanching.



7. Following sterile prep, the vasectomy may proceed immediately.



8. The ring clamp is applied between the 2nd and 3rd pair of pin-point injection marks. The ring clamp is applied between the 2nd and 3rd pair of pin-point injection marks.



References

1. Li S., Goldstein M., Zhu J., Huber D: The No-Scalpel Vasectomy. J. Urol 1991; 145; 341-4.
2. Huber D.: No-Scalpel Vasectomy: The transfer of a refined surgical technique from China to other countries. Advances in Contraception. 1989; 5; 217-220
3. Nirathpongporn, A., Huber, D. and Krieger, J.N.: No-Scalpel Vasectomy at the King's birthday vasectomy festival. Lancet. 1990; 335; 894.
4. Viladoms, JM., Li, PS.: Vasectomija sin Bisturij. Arch. Esp. de Urol. 1994; 47; 695-701
5. V; Kaza RM; Singh I; Singhal S and Kumaran V : An evaluation of the No-Scalpel Vasectomy technique. BJU Int (England), Feb 1999, 83(3):283-284
6. Liu X, Li S: Vasal sterilization in China. Contraception, 1993; 48(3): 255-65
7. Li PS., Li S., Schlegel PN. Goldstein, M: External Spermatic Sheath injection for vasal nerve block. Urology; 199239:173-6
8. Wilson CL. No-needle anesthetic for no-scalpel vasectomy. [Letter] American Family Physician. 63(7):1295, 2001 Apr 1.
9. Weiss RS, Li PS: No-needle jet anesthetic technique for no-scalpel vasectomy. J. Urol 2005;173;1677-80.
10. Monoski, M, Li. PS, Baum N, Goldstein, M: No-needle and no-scalpel vasectomy. Urology, 68(1):9-14. July 2006
11. Ellis GI, Owens A. The efficacy and acceptability of using a jet injector in performing digital blocks. Am J Emerg Med. 1993;11:648-650.
12. Bennett J, Nichols F, Rosenblum M, Condry J. Subcutaneous administration of medazolam: a comparison of the Bioject jet injector with the conventional syringe and needle. J Oral Maxillofac Surg. 1998;56:1249-1254.
13. Munshi AK, Hegde A, Bashir N. Clinical evaluation of the efficacy of anesthesia and

patient preference using the needle-less jet syringe in a pediatric dental practice. *J Clin Pediatr Dent.* 2001;25:131-136.

14. Zsigmond EK, Darby P, Koenig HM, Goll EF. Painless intravenous catheterization by intradermal jet injection of lidocaine: a randomized trial. *J Clin Anesth.* 1999;11:87-94.

15. Cooper JA, Bromley LM, Baranowski AP, Barker SG. Evaluation of a needle-free injection system for local anaesthesia prior to venous cannulation. *Anesthesia.* 2000;55:247-250.